Signet Ring Cell Carcinoma of the Esophagus

Kevin Turner[1,2], Robert M. Genta[1,2], Amnon Sonnenberg[3]
[1]Miraca Life Sciences Research Institute, Irving, Texas; [2]University of Texas Southwestern Medical Center, Dallas, Texas; [3]Portland VA Medical Center, Portland, Oregon

UT Southwestern Medical Center

Miraca Life Sciences RESEARCH INSTITUTE

Background

Signet ring cell carcinoma is a histologic variant of adenocarcinoma characterized by a population of loose tumor cells whose cytoplasm appears almost entirely occupied by mucin.

In rare instances, signet ring cell carcinoma occurs at the gastroesophageal junction without association to any such primary lesion in other areas of the stomach.

Aims

The aim of the present cross-sectional study was to compare the clinical epidemiology of esophageal signet ring cell carcinoma with two groups of patients: those with non-signet ring esophageal adenocarcinoma and those with Barrett's esophagus without cancer.

Methods

Miraca Life Sciences is a specialized gastrointestinal laboratory, serving private outpatient endoscopy centers distributed throughout the entire United States. Over 1,500 individual gastroenterologists contributed to the database between Jan. 2008 and Dec. 2014.

From a total of 487,587 patients who had EGD with biopsies during the study period, we extracted the demographic, clinical, and histopathologic data of all patients who had a diagnosis of esophageal signet ring cell carcinoma, esophageal adenocarcinoma (EAC), or Barrett's esophagus (BE).

Socio-economic information was available from census data associated with the patients' postal address and ZIP codes.

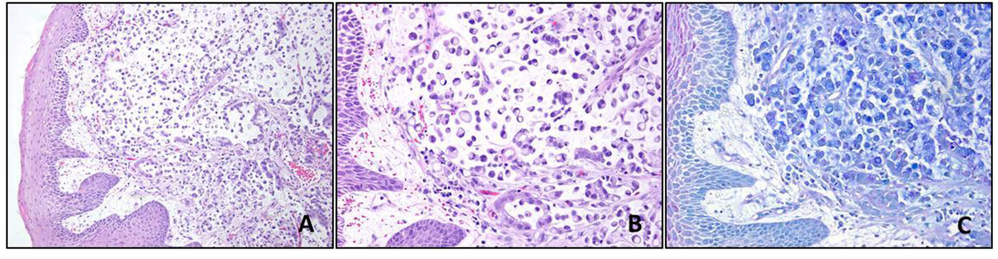

Figure 1 A) Hematoxylin and Eosin (HE) stain, low-power magnification: most of the tumor consists of poorly cohesive individual cells. B) HE, high-power magnification: almost every cell shows a round, pale cytoplasm and a peripherally located, flattened nucleus. C) Alcian Blue and Periodic Acid Schiff stain, high-power magnification, highlighting in dark blue the mucin content within the cytoplasm of the signet ring cells.

Patient characteristic	N	(%)
Total	94,731	(100%)
Mean age (SD)	63.8	(12.0)
Female	30,883	(33%)
Male	63,848	(67%)
Barrett's esophagus	91,802	(97%)
Esophageal adenocarcinoma	2,817	(3.0%)
Signet ring cell cancer	278	(0.3%)
Signet ring cell/all cancers	278	(9.0%)
Signet ring cell w BE	12	(4.3%)
Adenocarcinoma w BE	154	(5.5%)
All cancers w BE	166	(5.4%)

Table 1 General patient characteristics

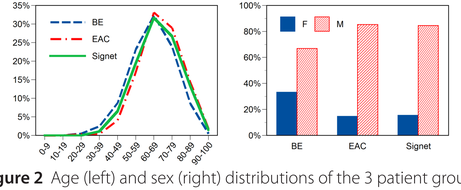

Figure 2 Age (left) and sex (right) distributions of the 3 patient groups

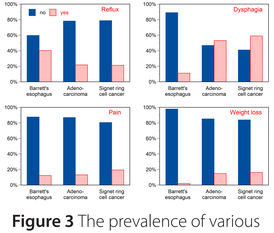

Figure 3 The prevalence of various symptoms among the 3 patient groups

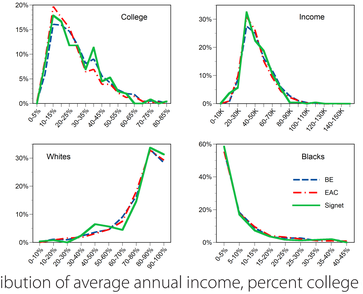

Figure 4 Distribution of average annual income, percent college education, and percent Whites or Blacks per residential ZIP codes among the 3 patient groups

Results

About 9% of all adenocarcinomas at the gastroesophageal junction harbored features of signet ring cell carcinoma.

Patients with both cancer types were slightly older than those with Barrett's esophagus and showed a striking male predominance.

Both cancer types were associated with a similar set of alarm symptoms, such as dysphagia, pain, and weight loss.

The distribution by race (Whites vs. Blacks) and socio-economic parameters (levels of college education or annual income) were similar among the 3 patient groups.

Conclusion

Patients with signet ring cell cancer are characterized by the same set of epidemiologic characteristics as patients with regular esophageal adenocarcinoma. The reasons why a minority of reflux patients progress to develop signet ring cell cancer rather than the usual type of esophageal adenocarcinoma remain presently unknown.

Conflicts of interest: None. Pursuant to 45 CFR 46, section 101b (4) – research was reviewed by Miraca Life Sciences Research Institute IRB.